



Knowledge and Confidence Regarding the Management of Perio-Endo Lesions; A Dentists' Survey in Riyadh, KSA

Khalid Alajlan^{1*}, Abdulaziz Almanea¹, Mohamed Algarni², Khalid Alshehri³, Abdullah Alhezam², Rakan Alsulaimani⁴, Yazeed Alturki⁴, Mohammed Alabbadi⁵, Fahad AlGhamdi⁵, Waleed AlMutairi³, Abdulaziz Alahmad³

¹National Guard Hospital, Primary Health Care, Riyadh, KSA.

²Ministry of National Guard Health Affairs, Riyadh, KSA.

³Division of Endodontics, King Abdulaziz Medical City, National Guard Health Affairs, Riyadh, KSA.

⁴National Guard Hospital, Riyadh, KSA.

⁵Ministry of Health, Riyadh, KSA.

ABSTRACT

Due to their destructive impact on the tooth structure and the supporting periapical tissues, endodontic-periodontal lesions provide a significant challenge for the dentist in their care (i.e., bone and periodontal membrane). A thorough history is crucial to identifying the root of the problem and accurately diagnosing the patient's condition.

This is a cross-sectional study conducted among 500 dentists in Riyadh using an online survey using convenient sampling. An online questionnaire was used consisting of questions related to demographic data followed by questions including knowledge, attitude, and confidence toward handling perio-endo lesions in clinics. 66% of the participants preferred referring EPL patients to specialists. 71% reported that using intra-canal medications can be useful in treating EPL. 58% revealed they did not have adequate knowledge regarding the successful management of EPL patients. The attitude of dental practitioners toward the treatment of Endo-Perio lesions is positive. But it does not correlate with their knowledge and practice.

Keywords: Perio-endo, Dentist's knowledge, Knowledge, Lesions.

HOW TO CITE THIS ARTICLE: Alajlan Kh, Almanea A, Algarni M, Alshehri Kh, Alhezam A, Alsulaimani R, et al. Knowledge and Confidence Regarding the Management of Perio-Endo Lesions; A Dentists' Survey in Riyadh, KSA. Entomol Appl Sci Lett. 2022;9(3):45-9. <https://doi.org/10.51847/LEFHGNjWO>

Corresponding author: Khalid Alajlan

E-mail ✉ Dr.alajlan4@hotmail.com

Received: 07/04/2022

Accepted: 27/08/2022

INTRODUCTION

There are clear correlations between the pulp and the periodontium, which have been reported in several investigations. When the pulp becomes infected, the periodontal tissues may also become infected. Tooth loss due to endo-perio lesions is more likely than loss due to either endodontic or periodontal diseases alone. Successful therapy requires cooperation between endodontists and periodontists to eradicate endodontic and periodontal diseases [1, 2].

Endodontic infection, periodontal disease, or the combination of the two in the form of endo-perio lesions result in almost 50% of all cases of tooth loss (EPL). The close anatomic and functional relationship between endodontic and periodontal tissues leads to the development of combined EPL. The pulp and the periodontium develop from the same embryological and morphological precursor. A multidisciplinary approach is necessary due to the similarities in the pathophysiology of the two diseases and the many routes that link them. A great deal has been written about these lesions throughout the years,

yet doctors still have trouble identifying and treating them [3, 4].

The success rates for endodontic therapy conducted in normal dental practice. Apical periodontitis is common among root-filled teeth (22-61%), and radiographically insufficient root fillings are common (47-86%), according to many cross-sectional studies conducted on populations in various countries [5, 6].

The involvement of both the pulp and the periodontal disease in the same tooth has been identified as a hallmark of endodontic-periodontal diseases. Because a single lesion may exhibit endodontic and periodontal involvement symptoms, diagnosis may be difficult [7].

Classification

Class I-primary endodontic lesion

Apical foramen, followed by accessory and lateral canals, and finally dentinal tubules, are the most common sites of initiation and maintenance of endodontic diseases. Increased intra-pulpal pressure and cell death are the outcomes of edema brought on by these inflammatory lesions [8].

The venous component of the local microvasculature collapses because of inflammatory exudates. This leads to hypoxia and anoxia in the affected area, which triggers necrosis and subsequent edema due to chemical mediators. Root-cause periodontitis is inflammation of the periodontal tissues caused by irritants in the tooth's root canal. Clinically, this situation may be like that of a periodontal abscess. A sinus tract extending from the pulp and connecting to the periodontal ligament is more likely. The situation is analogous when a molar tooth's coronal draining spreads into its furcation regions. The existence of lateral canals from a necrotic pulp into the furcation region further increases the risk of this happening. Once root canal treatment is performed, primary endodontic lesions often recover. Suppose the afflicted necrotic pulp is extracted and the root canals are thoroughly cleaned and obturated. In that case, the sinus tract that extends into the gingival sulcus or furcation region will quickly heal and vanish [9, 10].

Class II primary periodontal lesion

Periodontal microorganisms are the primary culprits in the development of lesions. This is

how chronic periodontitis spreads farther and further up the root. Pulpal testing has often shown a normal clinical response from the pulp. Plaque and calculus buildup is common, and so is the appearance of deeper, larger pockets. The periodontal disease stage and how well it is treated will determine the prognosis [11, 12].

Class III: primary periodontal disease with periodontal involvement

Without prompt treatment, suppurating primary endodontic illness can potentially become secondary associated with periodontal disintegration at the gum line. When plaque builds up along the sinus tract's gingival edge, it may cause a condition called plaque-induced periodontitis. Both the treatment and prognosis for teeth vary depending on whether plaque and calculus are present or not. Both endodontic and periodontal care will be needed to save the tooth. Root perforation during root canal therapy, or misplaced pins or posts during coronal restoration, may also cause primary endodontic diseases with subsequent periodontal involvement. Periodontal pockets might deepen locally, or an acute periodontal abscess can occur. Root fractures may manifest as primary

endodontic diseases or as secondary periodontal involvement. Following root canal treatment, the patient waits a certain length of time to enable the gums to recover. If periodontal treatment is needed, it is performed after an assessment period of a few months. The severity of periodontal diseases and the quantity of attachment loss determine the prognosis [13]. Due to their destructive impact on the tooth structure and the supporting periapical tissues, endodontic-periodontal lesions provide a significant challenge for the dentist in their care (i.e., bone and periodontal membrane). A thorough history is crucial to identifying the root of the problem and accurately diagnosing the patient's condition [14]. In the microbiology of EPL, it was observed that the pathogens that cause disease in the root canal and periodontal pocket are similar to each other. These bacteria, also known as red and orange complex, include *Porphyromonas gingivalis*, *Tannerella Forsythia* and *Fusobacterium*, *Prevotella*, and *Treponema* species [15].

Primary periodontal disease and primary endodontic disease are often easy to diagnose

clinically. It is called primary endodontic disease when the pulp is diseased and dead. The pulp is alive and may be detected by testing in cases of primary periodontal disease. True mixed illnesses, which include primary endodontic disease with secondary periodontal involvement or primary periodontal disease with secondary endodontic involvement, are quite similar clinically and radiographically. Soft tissue healing on clinical probing and bone healing on a recall radiograph is required for a reliable retrospective diagnosis of mainly endodontic illness after the lesion has been treated for the absence of signs of plaque-induced periodontitis [16].

Aims of the study

- To determine the knowledge, attitude, and confidence of dentists regarding the management of perio-endo lesions.

MATERIALS AND METHODS

Study design

This is cross-sectional research of 500 dentists in Riyadh, Saudi Arabia, and it was done using an online survey to maximize convenience. Research Methods A web-based questionnaire was used to gather information on participants' demographics and their level of understanding of and confidence in discussing perio-endo lesions in clinical settings.

Instrument validity and reliability

A pilot study in which 20 individuals were questioned through email. The resulting data were imported into SPSS version 22 for analysis using Chronbach's alpha to evaluate internal consistency. Sending the questionnaire to seasoned REU researchers allowed us to assess its validity and adjust based on their input.

Statistical analysis

Descriptive statistics were run on the collected data using SPSS version 22 for analysis.

IRB approval

To gather data, this study first sought and received IRB permission after registering its proposal on the REU research center's online site. (#FRP/2021/399/609/584).

RESULTS AND DISCUSSION

Findings revealed that out of the total of 500 dentists participating in this study, 65% were males and 35% were females (**Figure 1**). As far as work experience was concerned, 45% had less than 5 years of experience, 35% had 5 to 10 years and 20% had more than 10 years (**Figure 2**). **Table 1** shows the responses of dentists when inquired about the confidence and perception of endo-perio lesions. It was noteworthy to mention that 41% believed they could handle a patient with EPL. 66% of the participants preferred referring EPL patients to specialists. 71% reported that using intra-canal medications can be useful in treating EPL. 58% revealed they did not have adequate knowledge regarding the successful management of EPL patients. Only 15% reported being capable of performing hemisection or root amputation-related procedures in their routine practice. When inquired about their preference, 66% preferred performing endodontic therapy first followed by periodontal treatment. 55% disclosed that their patients were motivated to undergo complicated endo-perio-related treatment procedures. Finally, a high majority of participants (88%) believed that knowledge and practice of treating EPL patients should be incorporated during their undergraduate education.

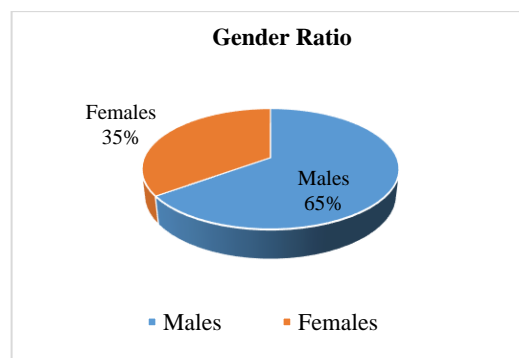


Figure 1. Gender ratio of survey participants

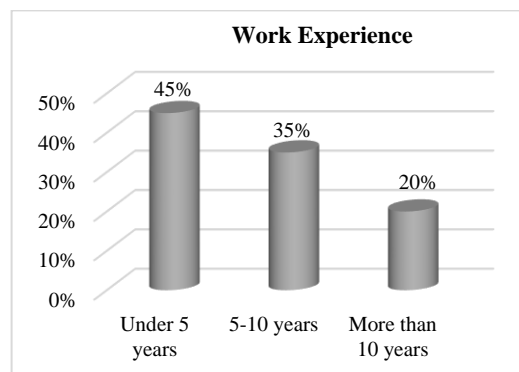


Figure 2. Work experience of study participants

Table 1. Responses of study participants towards the survey questions

Questions	Responses
In your professional practice, do you deal with endo-perio lesions?	Yes: 41% No: 59%
Would you consult with professionals on these aspects?	Yes: 66% No: 34%
Can Endo-perio lesions be treated with intra-canal medicaments?	Yes: 71% No: 29%
Do you feel confident in your ability to deal with such situations?	Yes: 42% No: 58%
To what extent do you have experience with hemisection, root amputation, and other advanced endodontic and periodontal surgical techniques?	Yes: 15% No: 85%
In certain endo-perio lesions, root canal therapy or periodontal treatment must be performed initially.	Endodontic therapy: 66% Periodontal treatment: 34%
Is there sufficient motivation for patients in your clinical practice to undergo difficult treatments to cure these lesions?	Yes: 55% No: 45%
Do you agree that there needs to be greater emphasis on treating endo-periosteal lesions in undergraduate programs?	Yes: 88% No: 12%

The results show that dentists have a favorable outlook on caring for EPL patients, but their knowledge and practice fall short of expectations. Among 63 dentists, Khandelwal *et al.* (2020) did descriptive survey research. The dentists tested their ability to treat endo-perio lesions and their familiarity with the difficulties of dealing with combined lesions. As few as 31% of dentists, including experts, have the skills necessary to treat EPL patients successfully. Yet, 92 percent of respondents agreed that more EPL management coursework should be available to undergraduates. This concludes that accurate identification of Endo-perio lesions is crucial for selecting the most appropriate therapy and maximizing treatment outcomes. Doctors may have difficulties treating EPL since it often requires input from many specialties. Our results are consistent with those cited above. Another research by Kabore *et al.* (2022) found that 70% of the practitioners examined had an above-average understanding of the diagnosis, while 98% had above-average expertise in treatment and prognosis approaches to EPLs [17]. Some 85.5% of the professionals I spoke with had a fair to strong understanding of EPL management. However, gaps in our

understanding of diagnostic factors exist. This might lead to problems in the treatment of this disease. The expertise in the previous research was noticeably higher than in our own.

Since the etiology and pathophysiology of pulpitis and apical periodontitis are now well-understood, general dentists may and should aim for the highest success rate possible while doing endodontic treatment, as reported by Siddiqui *et al.* (2022) [18]. Root perforation, fractures, and dental abnormalities are all variables that might facilitate the development of lesions in the pulp and apical periodontium, which are most often caused by bacterial and viral infections. Only 31% of dentists and 12% of experts were able to handle these types of patients successfully. Primary endodontic lesions often heal after receiving appropriate endodontic treatment. When it comes to endodontic-periodontal lesions, the prognosis and treatment options might change based on the underlying cause, mechanism of damage, and accuracy of the diagnosis. Their research showed that the majority of patients (77.7%), those who reported endodontic therapy followed by periodontal therapy (15.7%), those who reported RCT alone (6%), and those who reported periodontal therapy followed by endodontic therapy (6%), were all properly informed about how to treat primary endo secondary perio lesions. Endodontic treatment was used by 43.9% of people who reported having a primary perio secondary endo lesion treated, while the remaining 56.1% of people used periodontal therapy.

CONCLUSION

- The attitude of dental practitioners toward the treatment of Endo-Perio lesions is positive. But it does not correlate with their knowledge and practice.
- There is a need of improving the knowledge of dentists regarding the treatment of patients with endo-perio lesions.

ACKNOWLEDGMENTS: We would like to acknowledge the support of the research center of Riyadh Elm University.

CONFLICT OF INTEREST: None

FINANCIAL SUPPORT: None

ETHICS STATEMENT: This study was registered in the Riyadh Elm University research center portal and received ethical approval.

REFERENCES

1. Makeeva MK, Daurova FY, Byakova SF, Turkina AY. Treatment of an endo-perio lesion with ozone gas in a patient with aggressive periodontitis: A clinical case report and literature review. *Clin Cosmet Investig Dent.* 2020;12:447.
2. Shrwani RJ, Alshammari BZ, AlShammari RA, Alshammari RH, Alshammari MA, Alturki RF, et al. An overview on periodontal–endodontic lesions diagnosis and management: A literature review. *Ann Dent Spec.* 2021;9(1):84.
3. Dakó T, Lazăr AP, Bică CI, Lazăr L. Endo-perio lesions: Diagnosis and interdisciplinary treatment options. *Acta Stomatol Marisiensis J.* 2020;3(1):257-61.
4. Albadr AK, Alqab MK, AlRabiah A, Alamoudi SA, Hassna MA, Binmoamar AA. Evaluation of knowledge among dental patients regarding root canal symptoms and treatment. *Ann Dent Spec.* 2020;8(4):105.
5. Selivany BJ, Abdulkareem SS. General dental practitioners perception toward endo-perio lesions in primary health care center in Kirkuk city. *J Duhok Univ.* 2022;25(1):26-30.
6. Hajihassani N, Tofangchiha M, Namdari P, Esfehiani M. Evaluation of the ability of senior dental students of qazvin faculty of dentistry to interpret diagnostic periapical radiographs. *Ann Dent Spec.* 2018;6(3):299-303.
7. Al-Fouzan KS. A new classification of endodontic-periodontal lesions. *Int J Dent.* 2014;2014.
8. Singh P. Endo-perio dilemma: a brief review. *Dent Res J.* 2011;8(1):39.
9. Peeran SW, Thiruneervannan M, Abdalla KA, Mugrabi MH. Endo-perio lesions. *Int J Sci Technol Res.* 2013;2(5):268-74.
10. Alshehri AA, Alzain SM, Alnaim AJ, Alrumaih JM, Naji A, Dewedar MMA, et al. Root canal morphology and its relationship to endodontic procedures. *Ann Dent Spec.* 2020;8(2):94.
11. Ahmed HM. Different perspectives in understanding the pulp and periodontal intercommunications with a new proposed classification for endo-perio lesions. *ENDO (Lond Engl).* 2012;6(2):87-104.
12. Giovannoli JL, Rocuzzo M, Albouy JP, Duffau F, Lin GH, Serino G. Local risk indicators–Consensus report of working group 2. *Int Dent J.* 2019;69:7-11.
13. Devaraj SD, Prabhakar J. Endo-Perio Lesion- A Brief Review. 2013.
14. Alquthami H, Almalik AM, Alzahrani FF, Badawi L. Successful management of teeth with different types of endodontic-periodontal lesions. *Case Rep Dent.* 2018;2018.
15. Çirakoğlu NY, Karayürek F. Knowledge and awareness levels of dentists' about the endo-perio lesions: the questionnaire-based research. *Adıyaman Üniv Sağlık Bilim Derg.* 2020;7(1):64-70.
16. Khandelwal A, Billore J, Gupta B, Jaroli S, Agrawal N. Knowledge, attitude and perception on endo-perio lesions in practicing dentists-A qualitative research study. *J Adv Med Dent Sci Res.* 2020;8(11):31-4.
17. Kabore WA, Garé JV, Koama C. Diagnostic and therapeutic approaches to endodontic-periodontal lesions: A survey among dental surgeons in Ouagadougou, Burkina Faso. *Saudi Endod J.* 2022;12(2):195.
18. Siddiqui AY, Radhan R, Almalki F, Alghamdi F, Alsubhi A, Alaamri A, et al. Knowledge and awareness of Endo-Perio lesions among dentists and dental interns in Saudi Arabia. 2022.