



Skin Manifestations as Early Presenting Symptom of COVID-19 in Acute Myeloid Leukemia

Maryam Barkhordar^{1*}, Seied Asadollah Mousavi¹, Amirabbas Rashidi¹, Masoumeh Khataee Khosroshahi¹, Sahar Tavakoli¹, Fariba Tahsili¹

¹Hematology-Oncology and BMT Research Center, Tehran University of Medical Sciences, Tehran, Iran.

ABSTRACT

Coronavirus infection in 2019 (COVID-19) is an acute respiratory infection caused by a coronavirus, and it has been associated with various organ involvement. However, there are few examples of COVID-19's unusual appearance in newly diagnosed acute myeloid leukaemia (AML). Through two case reports and a literature review, this report aims to provide an overview of cutaneous characteristics in COVID-19 individuals. In this study, we present two patients with AML who developed a diffuse maculopapular rash as an early indication of COVID-19. Our patients exhibited lung involvement and chest imaging characteristics consistent with COVID-19, as well as similar cutaneous manifestations. However, the COVID-19 RT-PCR became positive only in the first case at once. The various symptoms of COVID-19 are thought to be the result of an overwhelming immune response to coronavirus, which produces acute inflammation and tissue damage such as vasculitis and other skin lesions. Given the strategic importance of early COVID-19 diagnosis, particularly for malignant disorders, it is crucial to address the possibility of COVID-19 presenting with dermatologic manifestations.

Keywords: Acute myeloid leukemia, COVID-19, Cutaneous manifestations, Initial presenting symptoms.

HOW TO CITE THIS ARTICLE: Barkhordar M, Mousavi S A, Rashidi A, Khosroshahi M K, Tavakoli S, Tahsili F. Skin Manifestations as Early Presenting Symptom of COVID-19 in Acute Myeloid Leukemia. Entomol Appl Sci Lett. 2021;8(3):80-4. <https://doi.org/10.51847/1iAMD6Vdaj>

Corresponding author: Maryam Barkhordar

E-mail ✉ mbarkhordar@sina.tums.ac.ir

Received: 29/03/2021

Accepted: 23/08/2021

INTRODUCTION

The occurrence of the COVID-19 pandemic caused by a coronavirus (SARS-CoV-2) is one of the biggest challenges currently facing the medical community with more than 20 million cases worldwide. Numerous studies have reported clinical presentations and outcomes of COVID-19 in previously healthy persons. Also, there are a few reports regarding outcomes or presentation of COVID-19 in patients with a history of malignancy and immunosuppressive therapy [1-3].

There are different opinions about the impact of immunosuppressing drugs and disease on the incidence, manifestations, severity, and outcome of COVID-19 in people with malignant diseases compared to non-malignant. In a Chinese study,

it is reported that COVID-19 patients with cancer had a higher risk of respiratory failure and ICU admission [4].

Another study in immunosuppressed post-transplantation patients did not show a higher risk of severe events of COVID-19 [5]. The respiratory tract is the primary site of infection for COVID-19 with symptoms ranging from a flu-like symptom to fulminant pneumonia and respiratory failure [6].

The diagnostic assay for SARS-CoV-2-infection by RT-PCR is a gold standard test for diagnosis of COVID-19 which has high specificity and low sensitivity (30–50%) [7]. While the chest CT positive rate was more than 90% in highly suspected cases [8]. So it was recommended to do a lung CT scan as the main diagnostic and screening basis for COVID-19.

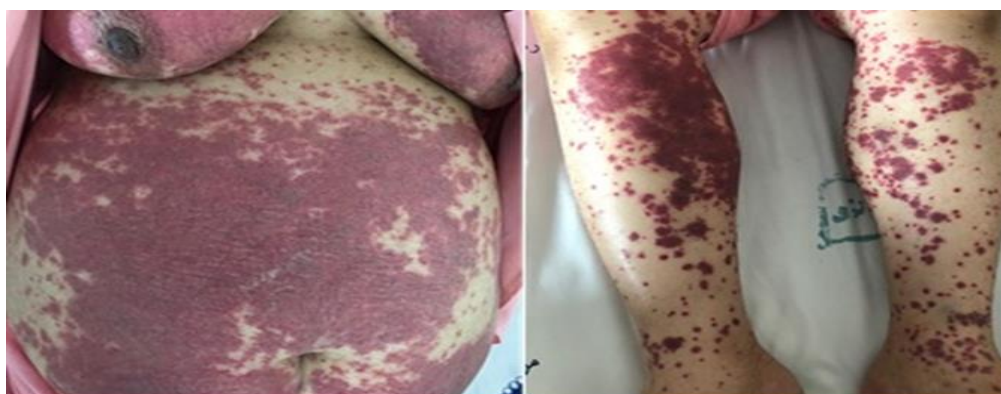
Different organs could be affected by COVID-19. There are few descriptions of the cutaneous manifestations of COVID-19. Skin lesions as a manifestation of COVID-19 have been reported in some case reports and case series [9-11]. Most of the reported skin lesions in COVID-19 are urticarial and maculopapular rash that may have many differential diagnoses, such as drug reactions and other viral infections. Various theories have been proposed about the mechanisms of cutaneous manifestations in COVID-19 infection. These could be the direct effect of COVID-19 or might be indirect complications leading to vascular occlusion or damage [12, 13]. One hypothesis is that immune complexes against the viral particles that appear in the skin blood vessels could lead to a type of vasculitis. Also, it could be postulated that Langerhans cells activation due to immune response to the virus, without the direct involvement of keratinocytes, can lead to vasodilation and spongiosis [14]. The purpose of this article is to report two cases of AML with fever and various cutaneous manifestations as presenting symptoms of COVID-19 and provide a literature review of various cutaneous manifestations in patients with COVID-19.

MATERIALS AND METHODS

Patients' demographic, clinical, and laboratory data were gathered from their medical records. Two individuals consented in writing to the use of their data. A review of the literature was conducted to know the documented dermatologic symptoms of COVID-19.

RESULTS AND DISCUSSION

Case-1

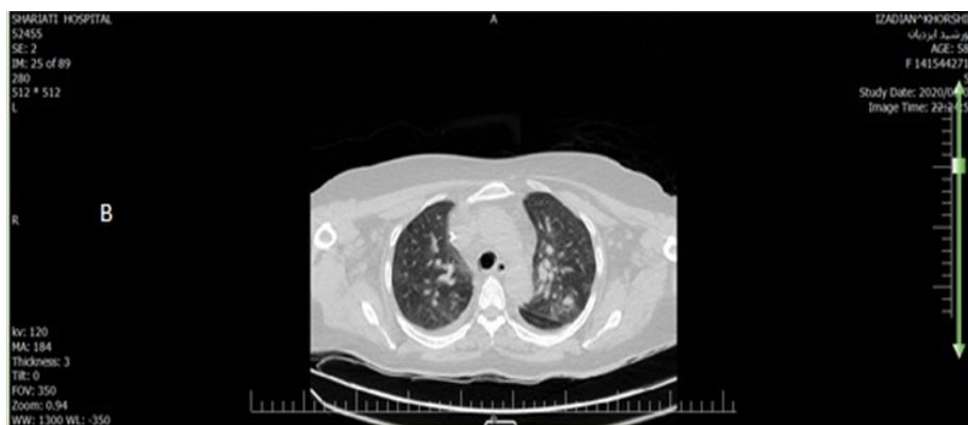


a)

A 56-year-old woman was admitted to the hematology department with pancytopenia as an initial diagnosis of acute leukemia. No splenomegaly or lymphadenopathy was detected in clinical examination.

Bone marrow samples were analyzed for morphologic, immunophenotypic, and genetic evaluation, and AML M4 (acute myelomonocytic leukemia) was diagnosed. A normal female karyotype (46, XX) was reported in the routine cytogenetic analysis. Molecular assays were performed, NPM1 mutation and concurrent FLT3-ITD mutation with a low allelic ratio (36%) were detected.

Induction chemotherapy for AML with standard (7 + 3) regimen was started (Cytarabine, 100mg/m²/day in D1-D7 + Idarubicin, 12mg/m²/day in D1-D3). 2 weeks after induction chemotherapy the patient developed prolonged cytopenia, fever, maculopapular rash, and urticaria on the abdomen and legs (**Figure 1a**). Fever workup was done and empirical antibiotic therapy started. At this time, no positive findings were found in favor of infection in cultures, lung CT scans, and other assessments. In the following days, the skin lesions progressed as diffuse maculopapular exanthema, palpable purpuric lesions, and hemorragic macular rash on the legs which were accompanied by generalized edema, itching, arthralgia, and persistence of neutropenic fever. After four weeks the imaging was repeated and the second chest CT scan showed bilateral ground-glass and patchy opacities highly suggestive of COVID-19 infection (**Figure 1b**).



b)

Figure 1. a) Diffuse maculopapular exanthema, hemorrhagic macular rash on the legs of an AML patient with COVID-19 infection. b) Bilateral ground-glass and patchy opacities highly suggestive of COVID-19 infection in the first patient two weeks after first imaging.

The patient remained cytopenic, and the CRP level was high (ranged 70-120 mg/L). Infection with SARS-CoV-2 was confirmed by RT-PCR and she was transferred to isolation wards in the department of infectious disease. After two weeks, cutaneous manifestation and fever were improved and the bone marrow aspiration/biopsy was in remission with incomplete hematologic recovery.

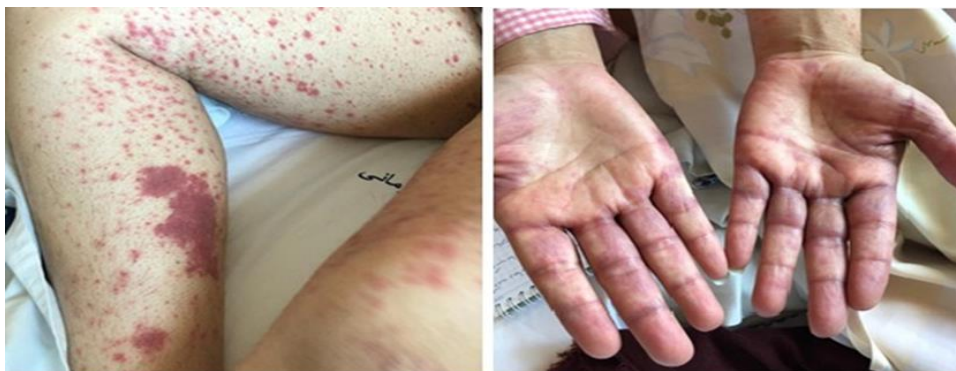Case-2

A 42-year-old woman with a diagnosis of AML-M1 was admitted to the hematology department for induction therapy. Her initial CBC included a WBC count of 59000/mm³ with more than 50% blasts in peripheral blood, hemoglobin of 7 g/dL, and a platelet count of 30,000/mm³.

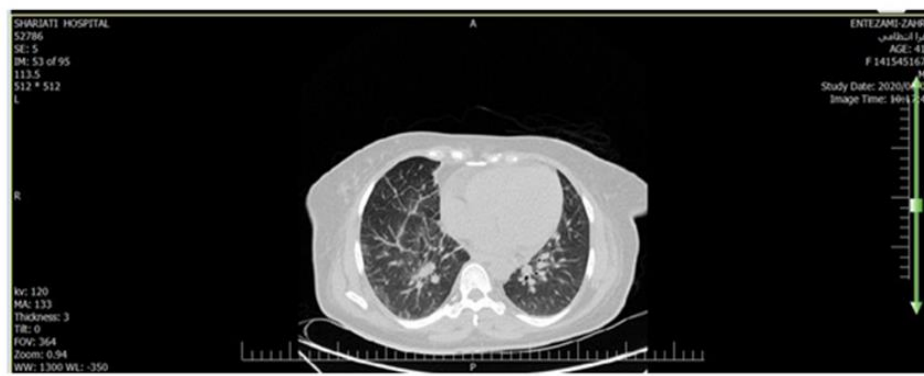The diagnosis was confirmed based on morphology and immune-phenotyping analysis of bone marrow aspiration. Normal female karyotype (46, XX) with mutated NPM1 and FLT3-ITD was reported in the cytogenetic and molecular study.

Ten days after the end of induction chemotherapy with (7 + 3) regimen, she suffered from maculopapular rash, spreading to the legs that further developed to multiple, diffuse, non-blanching purpura scattered on the distal lower and upper extremities and trunk over a few days (**Figure 2a**).

She also complained of itching and arthralgia but did not have a cough or any respiratory symptoms. She was febrile with a high level of CRP (77 mg/l) and negative blood cultures and a normal lung CT scan (**Figure 2**). Twenty days after induction chemotherapy, WBC count of 800/mm³, hemoglobin of 7.4 g/dL, and platelet count of 50,000/mm³ were reported. On day 16th bone marrow evaluation was hypocellular with less than 5 % blast. Within 12 days from first imaging, the lung CT scan was suggestive of COVID-19 infection (**Figure 2b**), and she was transferred to isolation wards for supportive therapy but RT-PCR was negative at once. Notably, both patients were in the same room for a week at their initial admission.



a)



b)

Figure 2. a) Multiple, diffuse, non-blanching purpura scattered on the distal lower and upper extremities and trunk within neutropenic fever after induction chemotherapy. b) Bilateral patchy ground-glass opacity suggestive of COVID-19 infection after 12 days from first normal imaging in the second patient.

COVID-19 may have an impact on several organs. However, there are few examples of cutaneous symptoms of COVID-19 as an early presenting finding in a newly diagnosed acute myeloid leukemia (AML). It is, to the best of our knowledge, the first report of COVID-19-related cutaneous symptoms in two newly diagnosed AML patients with concurrent SARS-CoV-2 infection.

We documented two patients with newly diagnosed acute myeloid leukemia who presented similar clinically and had lung CT scan findings consistent with COVID-19 infection. An exciting finding was that both patients presented with comparable skin symptoms of varied severity as their initial presentation of COVID-19 infection.

Both patients developed a diffuse maculopapular rash that began on the lower extremities and progressed to the trunk, upper extremities, and macular hemorrhagic rash on the legs associated with mild arthralgia, and edema. Excessive immune response to the coronavirus through the inflammation of the blood vessels could explain the skin lesions. Recalcati *et al.* in Italy introduced 88 COVID-19 patients, one-fifth of whom (18/88) had various cutaneous manifestations, mostly erythematous eruptions or urticaria [9].

The information of 72 COVID-19 patients with cutaneous manifestations that were reported in 15 case series and case report studies are summarized in a review by M. Sachdeva, *et al.* They reported that maculopapular exanthema and papulovesicular rash were the most common skin manifestation of COVID-19, presenting in 36% and 34.7% of patients, respectively [10].

Another study in Spain has described five different cutaneous patterns associated with COVID-19 in 375 cases and showed that cutaneous manifestations are associated with different duration, severity and prognosis and appear at different times in the course of the disease [11].

No symptoms of pneumonia such as cough or dyspnea were seen in our patients. At our center, RT-PCR for SARS-CoV-2 is performed only once for suspected patients. So infection with SARS-CoV-2 was confirmed by RT-PCR only in the first patient. The second case, although clinical and imaging findings were suggestive of COVID-19, was not confirmed by RT-PCR at once. Our cases received supportive care, antibiotic therapy, and hydroxychloroquine in the isolation ward. Lesions spontaneously improved within 2 weeks in both patients.

CONCLUSION

In conclusion, the new skin lesions might be early indications of COVID-19. Given the importance of rapid COVID-19 diagnosis, particularly for malignant disorders, it is crucial to evaluate probable dermatologic features as the earliest COVID-19 presentation. However, more study is needed to verify and describe the rare manifestation of COVID-19 in immunocompromised individuals.

ACKNOWLEDGMENTS: None

CONFLICT OF INTEREST: None

FINANCIAL SUPPORT: None

ETHICS STATEMENT: The patients provided written informed consent for the release of their data.

REFERENCES

1. Yu J, Ouyang W, Chua MLK, Xie C. SARS-CoV-2 Transmission in Patients With Cancer at a Tertiary Care Hospital in Wuhan, China. *JAMA Oncol.* 2020;6(7):1108-10. doi:10.1001/jamaoncol.2020.0980.
2. The Lancet Oncology. COVID-19: global consequences for oncology. *Lancet Oncol.* 2020;21(4):467. doi:10.1016/S1470-2045(20)30175-3.
3. Xia Y, Jin R, Zhao J, Li W, Shen H. Risk of COVID-19 for patients with cancer. *Lancet Oncol.* 2020;21(4):e180. doi:10.1016/S1470-2045(20)30150-9.
4. Liang W, Guan W, Chen R, Wang W, Li J, Xu K, et al. Cancer patients in SARS-CoV-2 infection: a nationwide analysis in China. *Lancet Oncol.* 2020;21(3):335-7. doi:10.1016/S1470-2045(20)30096-6.
5. D'Antiga L. Coronaviruses and Immunosuppressed Patients: The Facts During the Third Epidemic. *Liver Transpl.* 2020;26(6):832-4. doi:10.1002/lt.25756.
6. Zhai P, Ding Y, Wu X, Long J, Zhong Y, Li Y. The epidemiology, diagnosis and treatment of COVID-19. *Int J Antimicrob Agents.* 2020;55(5):105955. doi:10.1016/j.ijantimicag.2020.105955.
7. Bai L, Wang M, Tang XQ. Thinking about the hot issues in the diagnosis and treatment of novel coronavirus pneumonia. *Hua xi Med.* 2020;35(2):125-31.
8. Zhu N, Zhang D, Wang W, Li X, Yang B, Song J, et al. China Novel Coronavirus Investigating and Research Team. A Novel Coronavirus from Patients with Pneumonia in China, 2019. *N Engl J Med.* 2020;382(8):727-33. doi:10.1056/NEJMoa2001017.
9. Recalcati S. Cutaneous manifestations in COVID-19: a first perspective. *J Eur Acad Dermatol Venereol.* 2020;34(5):e212-3. doi:10.1111/jdv.16387.
10. Sachdeva M, Gianotti R, Shah M, Bradanini L, Tosi D, Veraldi S, et al. Cutaneous manifestations of COVID-19: Report of three cases and a review of literature. *J Dermatol Sci.* 2020;98(2):75-81.
11. Galván Casas C, Catala AC, Carretero Hernández G, Rodríguez-Jiménez P, Fernández-Nieto D, Rodríguez-Villa Lario A, et al. Classification of the cutaneous manifestations of COVID-19: a rapid prospective nationwide consensus study in Spain with 375 cases. *Br J Dermatol.* 2020;183(1):71-7.
12. Tang N, Li D, Wang X, Sun Z. Abnormal coagulation parameters are associated with poor prognosis in patients with novel coronavirus pneumonia. *J Thromb Haemost.* 2020;18(4):844-7. doi:10.1111/jth.14768.
13. Zhang Y, Xiao M, Zhang S, Xia P, Cao W, Jiang W, et al. Coagulopathy and Antiphospholipid Antibodies in Patients with Covid-19. *N Engl J Med.* 2020;382(17):e38. doi:10.1056/NEJMc2007575.
14. Gianotti R, Zerbi P, Dodiuk-Gad RP. Clinical and histopathological study of skin dermatoses in patients affected by COVID-19 infection in the Northern part of Italy. *J Dermatol Sci.* 2020;98(2):141-3.